

## Rifampicin Induced Hyperbilirubinemias: A Case Report

Rohit Bangwal<sup>1\*</sup>, Jagdish Rawat<sup>2</sup> and Dev Singh Jangpani<sup>2</sup>

<sup>1</sup>Department of Pharmacy Practice, Shri Guru Ram Rai University, India

<sup>2</sup>Department of Pulmonary Medicine, Shri Guru Ram Rai University, India

### 1. Abstract

Anti-tubercular therapy (ATT) induced hepatitis is a major problem which a physician encounters in his clinical practice. A case of 28-year-old female, weighing 45 kg was brought to hospital with the chief complains of low-grade fever for the past two months, cough, shortness of breath and 4-5 kg weight loss in two months. She had no history of hypertension (HTN), diabetes mellitus (DM), pulmonary tuberculosis (PTB). Her Chest X-ray showed right sided bilateral pulmonary TB and sputum acid fast bacilli (AFB) smear was repeatedly positive. Pulmonologist has started Category-I anti-tubercular regimen (Rifampicin, Isoniazid, Pyrazinamide and Ethambutol) under DOTS as per RNTCP guidelines. After 7 days of starting the treatment (DOTS regimen), she noticed yellowish discoloration of sclera, orange discoloration of urine but in spite of this she continued the drug for a further two weeks. Patient was found to be developing hepatotoxicity with the findings of elevated total bilirubin (10.2 mg/dl), conjugated bilirubin (2.5 mg/dl) and unconjugated bilirubin (7.2 mg/dl). Viral markers for hepatitis including hepatitis B viruses (HBsAg), hepatitis C viruses (HCV), human immunodeficiency virus (HIV), were all are non-reactive. Pulmonologist made provisional diagnosis of anti-tubercular drugs (specially rifampicin) induced hyperbilirubinemias.

Pulmonologist initially hold Rifampicin and Pyrazinamide, but started Isoniazid, Ethambutol, Ofloxacin, Pyridoxine along with liver enzyme. She showed gradual improvement as bilirubin after one-week had dropped down to 1.2 mg/dl. Rifampicin was added to the regimen and the serum bilirubin checked after 1 week was found 1 mg/dl. Pyrazinamide was added after repeated LFTs showed normal values. Patient continued her drugs and came for review after three months. She was advised to continue and complete the course of anti-tubercular drugs. Since Rifampicin is the most important first line anti-tubercular drug it is very important to restart this drug in order to have a satisfactory response to anti-tubercular therapy. We have reported this case because of its rarity in clinical practice. As a health care team member clinical pharmacist are need to be made aware of these potentially fatal adverse effects associated with anti-tubercular therapy via conduction of quality-based seminars, published medical literature, conferences, learning programs and health care camps.

**2. Keywords:** Tuberculosis; Rifampicin; Bilirubin; Anti-tubercular therapy; Pulmonologist

**\*Corresponding author:** Rohit Bangwal, Department of Pharmacy Practice, School of Pharmaceutical Sciences, Shri Guru Ram Rai University, Dehradun-248001, Uttarakhand, India, Tel: 8057671752, 6398161022; E-mail: [rohitbangwal93@gmail.com](mailto:rohitbangwal93@gmail.com)

**Received Date:** November 20, 2019; **Accepted Date:** November 23, 2019; **Published Date:** November 25, 2019

### 3. Introduction

Anti-tubercular drugs induced hepatitis is a major problem which a physician encounters in his clinical practice [1]. In view of increasing incidence of tuberculosis in our country a large number of infected individuals are started on Anti-tubercular (ATT) drugs and rifampicin is invariably part of the regimen [2]. One of the major adverse effects of ATT drugs is drug- induced hepatitis which is characterized by elevation of liver enzymes (SGOT, SGPT, ALT, GGT) and bilirubin levels (direct, indirect and total bilirubin) [3]. Hepatotoxicity is usually idiosyncratic or dose-dependent. Rifampicin causes transient elevation of transaminases in 5-10% of individuals and this does not warrant dose adjustments of the drug. Rarely rifampicin can lead to severe hepatitis with hyperbilirubinemia and marked elevations of SGOT and SGPT and in some patients this can be fatal [4]. The exact mechanism of Rifampicin induced hepatotoxicity is not known but it is postulated to be due to idiosyncratic reaction to rifampicin metabolites which may be directly toxic or induce an immunologically mediated liver injury [5,6]. Rarely rifampicin may cause hyperbilirubinemia without enzyme elevation. Here we report a patient with bilateral pulmonary tuberculosis who developed transient severe indirect hyperbilirubinemia on rifampicin [7]. On review of relevant literature, we find that rifampicin can have a biphasic effect on bilirubin, an initial increase in indirect bilirubin and later normalization of bilirubin. We have reported this case because of its rarity in clinical practice [8,9].

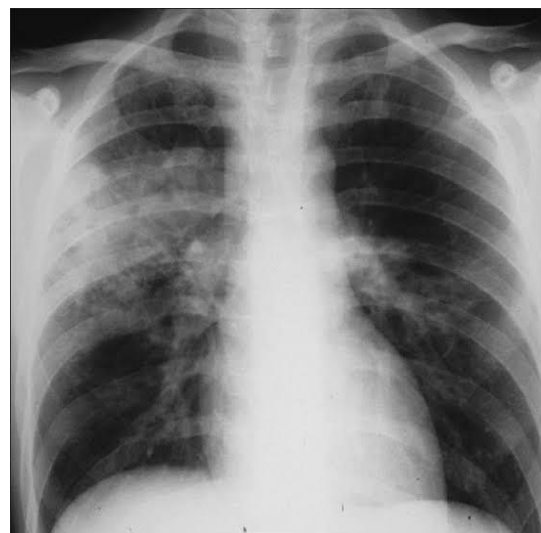
### 4. Case Presentation

A 28-year-old female working in the industry presented with low grade fever for the past two months, cough, shortness of breath and 5 kg weight loss in two months. Her Chest X-ray showed bilateral pulmonary TB and sputum AFB smear was repeatedly positive. She had been started on Category-1 anti-tubercular regimen (Rifampicin, Isoniazid, Pyrazinamide and Ethambutol) under DOTS as per

RNTCP guidelines. After 7 days of starting the medication she noticed yellowish discoloration of sclera but in spite of this she continued the drug for a further two weeks. Subsequently she had nausea and vomiting, fever, yellowish discoloration of skin and so came to our hospital. On clinical examination she was thin built, pale and deeply icteric. She had a tender hepatomegaly 2.5 cm below the right costal margin but spleen was not palpable. Cardiovascular system Abdomen and CNS were clinically normal. Fundus exam showed pale retina but the optic discs and vessels were normal.

### 4. Investigation

She had anaemia with haemoglobin of 10.6 gm/dl it means she had microcytic anaemia, blood picture suggestive of iron deficiency. Reticulocyte count was normal and Direct Coomb's Test negative. LFT: Total bilirubin: 10.2, Direct bilirubin 2.5 & indirect bilirubin 7.2 mg/dl (Predominantly indirect hyperbilirubinemia) and transaminases, LDH and alkaline phosphatase (ALP) were normal. Chest X-ray showed bilateral extensive pulmonary tuberculosis with cavitation in the right upper lobe.



**Figure 1:** Chest X-ray showed bilateral extensive pulmonary tuberculosis with cavitation in the right upper lobe.

Sputum was repeatedly positive for acid fast bacilli (AFB) and HIV, HBsAg and HCV antibody tests were negative. She was initially started on Isoniazid, Ethambutol, Ofloxacin, Pyridoxine along with liver enzyme. She showed gradual improvement after one-

week bilirubin had come down to 1.2 mg/dl. Rifampicin was added to the regimen and the serum bilirubin checked after 1 week was 1 mg/dl. After sputum culture she was started on amoxicillin-clavulanic acid in addition, to cover superadded bacterial infection. Pyrazinamide was added after repeated LFTs showed normal values. Patient became afebrile for one week after the course of amoxicillin-clavulanic acid, but again had fever spikes and Streptomycin was added to the regimen following which she became afebrile within 2 weeks. Patient continued her drugs and came for review after three months. She was afebrile and her appetite had improved. Her sputum samples became negative for AFB. She gained about 2 kg of weight. She was advised to continue and complete the course of anti TB drugs.

**Table 1:** Laboratory investigation.

Parameter	Test value	Test value	Normal value
LFT	(Day-1)	(Last Day)	
Hemoglobin	10.6	13.8	13-17 gm/dl
Total Bilirubin	10.2	1.4	0.2-1.3 mg/dl
Direct Bilirubin	2.5	0.9	0.0-0.8 mg/dl
Indirect Bilirubin	7.2	1.2	0.0-0.9 mg/dl
Mean cell volume	76	88	85-99 fl.

**Table 2:** Other investigation.

Radiological Investigation (CXR)	Chest X-ray showed bilateral extensive pulmonary tuberculosis with cavitation in the right upper lobe (Figure 1).
USG (Abdomen)	Tender hepatomegaly 2.5 cm below the right

	costal margin.
Coomb's Test (Immunohematology, Immunology)	Negative
General Blood Picture (GBP)	Microcytic anaemias (Iron Deficiency Anaemias)

## 6. Result and Discussion

Drug induced liver injury (DIH) has replaced the viral hepatitis as the most common cause of acute liver failure. Drug induced liver injury is most important side effect caused by Anti TB drugs. Drug induced liver injury is diagnosed only after excluding viral hepatitis. It is characterized by rise in SGOT, SGPT level more than three times normal and a fall in the SGOT, SGPT on stopping the drug. Re-challenge should cause a rise in SGOT and SGPT. Advanced age, female sex, alcoholism, hepatitis B and C virus, increased N-acetyltransferase (NAT) activity, underlying liver disease, reduced glutathione S-transferase activity, Human Immunodeficiency Virus (HIV) infection, and malnutrition are considered to be the major risk factors for ATT induced hepatitis. Rifampicin causing drug induced hepatitis occurs earlier than that caused by isoniazid and is characterized by patchy cellular involvement. Rifampicin causing drug induced hepatitis is considered to be a part of a systemic allergic reaction. We read many case reports like Gopi M et al. [3], this case report found that in normal subjects, the rise in the unconjugated bilirubin during the initial phase after administration of rifampicin (in the first week) closely followed the serum concentration of rifampicin. This observation suggests that the drug inhibits the clearance of the bilirubin by liver. Since only the unconjugated fraction is increased, rifampicin must be interfering in one or more of the following steps in bilirubin metabolism in the liver: (1) hepatocellular uptake (2) Intracellular protein binding (3) conjugation of bilirubin. When rifampicin therapy was continued, in the third week and fourth

week of therapy, indirect bilirubin levels was normalized and this observation suggests that this decrease in unconjugated bilirubin is due to increased hepatic clearance of the bilirubin induced by rifampicin. This biphasic effect of rifampicin on bilirubin is similar to what we observed in our patient. She had initial indirect hyper-bilirubinaemia which necessitated temporary discontinuation of the drug and reintroduction of the drug after 1 week did not evoke this response. It has been reported previously that rifampicin can occasionally cause unconjugated hyperbilirubinemia which is only subclinical without elevation of liver enzymes. However, in our patient, rifampicin caused marked clinical jaundice with unconjugated hyperbilirubinemia without elevation of liver enzymes and such an event is quite rare. In our patient anaemia along with elevated indirect bilirubin raised the possibility of a haemolytic process.

## 7. Conclusion

In patients with tuberculosis when a rifampicin containing anti-tubercular treatment is instituted, jaundice occurring within 1 week should suggest rifampicin toxicity. However, if only indirect hyperbilirubinemia is found and if haemolysis is excluded the patient may be restarted on rifampicin with close monitoring of bilirubin. Since Rifampicin is the most important first line anti TB drug it is very important to restart this drug in order to have a satisfactory response to anti-tubercular therapy. Clinicians need to be made aware of these potentially fatal adverse effects associated with anti-tubercular therapy via conduction of quality-based seminars, published medical literature, conferences, learning programs and health care camps.

## References

1. [Joint Tuberculosis Committee of the British Thoracic Society. Chemotherapy and management of](#)

[tuberculosis in the United Kingdom: recommendations 1998. Thorax. 1998; 53: 536-548.](#)

2. [Ostapowicz GM, Fontana R, Schidt F, Larson A, Davern T, Steven Han H, et al. Results of a prospective study of acute liver failure at 17 tertiary care centers in the United States. Ann Intern Med. 2002; 137: 947-954.](#)

3. [Benichou C. Criteria for drug-induced liver disorder: report of an international consensus meeting. J Hepatol. 1990; 11: 272-276.](#)

4. [Bangwal R, Joshi Y, Rawat S, Jangpani DS. Drug-induced hepatotoxicity of anti-tubercular drugs therapy: a case report. J Pharma Res. 2019; 8: 266-268.](#)

5. [Bangwal R, Rawat J, Joshi Y. Hepatitis Induced by Anti-Tubercular Therapy and Chronic Alcoholism: A Case Report. J Drug Deliv Therap. 2019; 9: 598-600.](#)

6. [Sharma SK, Balamurugan A, Saha PK, Pandey RM, Mehra NK. Evaluation of clinical and immunogenetic risk factors for the development of hepatotoxicity during antituberculosis treatment. Am J Respir Crit Care Med. 2002; 166: 916-919.](#)

7. [Kenwright S, Levi AJ. Sites for competition in selective hepatic uptake of rifampicin, flavaspidic acid, bilirubin and bromsulphthalein. Gut. 1974; 15: 220-226.](#)

8. [McColl KE, Thompson GG, El Omar E, Moore MR, Park BK, Brodie MJ. Effect of rifampicin on haem and bilirubin metabolism in man. Br J Clin Pharmacol. 1987; 23: 553-559.](#)

9. [Kadka J, Malla P, Jha SS, Poudel SR. The study of drug induced hepatotoxicity in ATT patients attending in national tuberculosis center in Bhaktapur. SAARC J Tuberculosis, Lung Dis HIV/AIDS. 2009; 6: 17-21.](#)

**Citation:** Rohit Bangwal, Jagdish Rawat, Dev Singh Jangpani. Rifampicin Induced Hyperbilirubinemias: A Case Report. SunKrist Clin Med Case Rep J. 2019; 1: 1003.

**Copy Right:** © 2019 Rohit Bangwal. This is an open-access article distributed under the terms of the Creative Commons Attribution License, which permits unrestricted use, distribution and reproduction in any medium, provided the original author and source are credited.